

JIA and uveitis

Dra. Beatriz H León

Universidad San Francisco de Quito

Ecuador





Initial presentation

BG, a 11 1/2 years old active boy had an URI followed by right knee pain that got worse during the following 4 weeks to the point that he could not bend it.

Over the last 2 weeks he also developed pain in both ankles, as well as swelling in right knee and ankles that made walking difficult, worst in the mornings. He complained of mild low back pain on the day of 1st appointment.

Parents reported a child previously active that was now quiet and still, very uncomfortable during the entire day.

They gave him acetaminophen and ibuprofen once or twice a day, on and off pattern with little improvement.

He is aA very good student that had missed 8 days of school in that month .

ROS. No weight loss, no fever, no rashes, no respiratory or GI symptoms.

Physical Exam. Weight above 75%, Height 50% BMI 21.9 (16.3-21.9)

Vital signs normal,

Severe swelling and pain in ankles, decrease ROM.

Effusion in right knee with supra-patellar effusion Decrease ROM

Schober 21 cm,

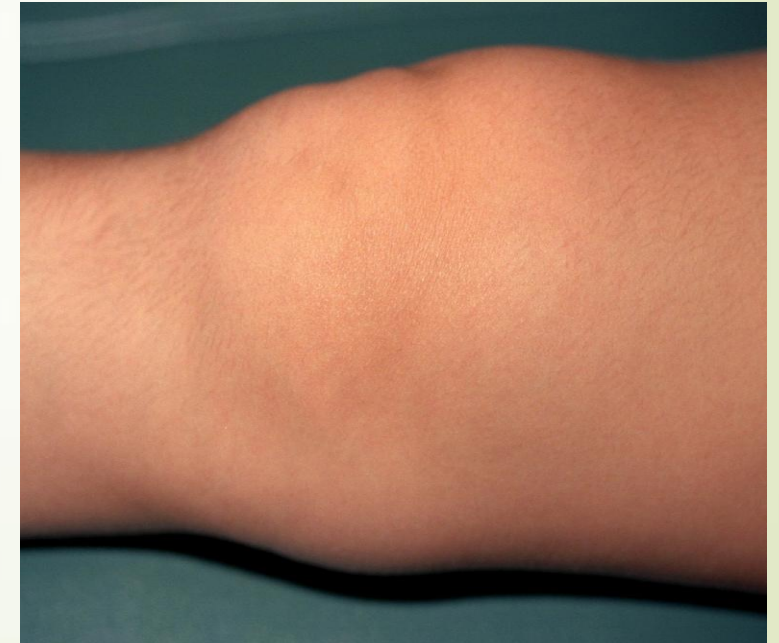No SI pain on pressure.

Previous medical history: Perennial allergic rhinitis.

Family history:

Father Type II diabetes

Grandmother Gastric CA



Laboratory and other studies

Labs:

WBC. 7.8: neut 46%, lymp 38 % mono 3% eos 8

Hct. 34 % (low for Quito's altitude)

490K/uL platelets

ESR:18 mm/1 hour

AST and ALT normal.

Rheumatoid Factor negative.

ANA negative

HLA-B27 negative

TNF 35 pg/m L (normal ≤ 8)

IgE: 89 IU

Ophthalmologic exam with slit lamp:
negative as well as each control every 6 months

Initial Diagnosis:

Oligoarticular JIA, ANA negative

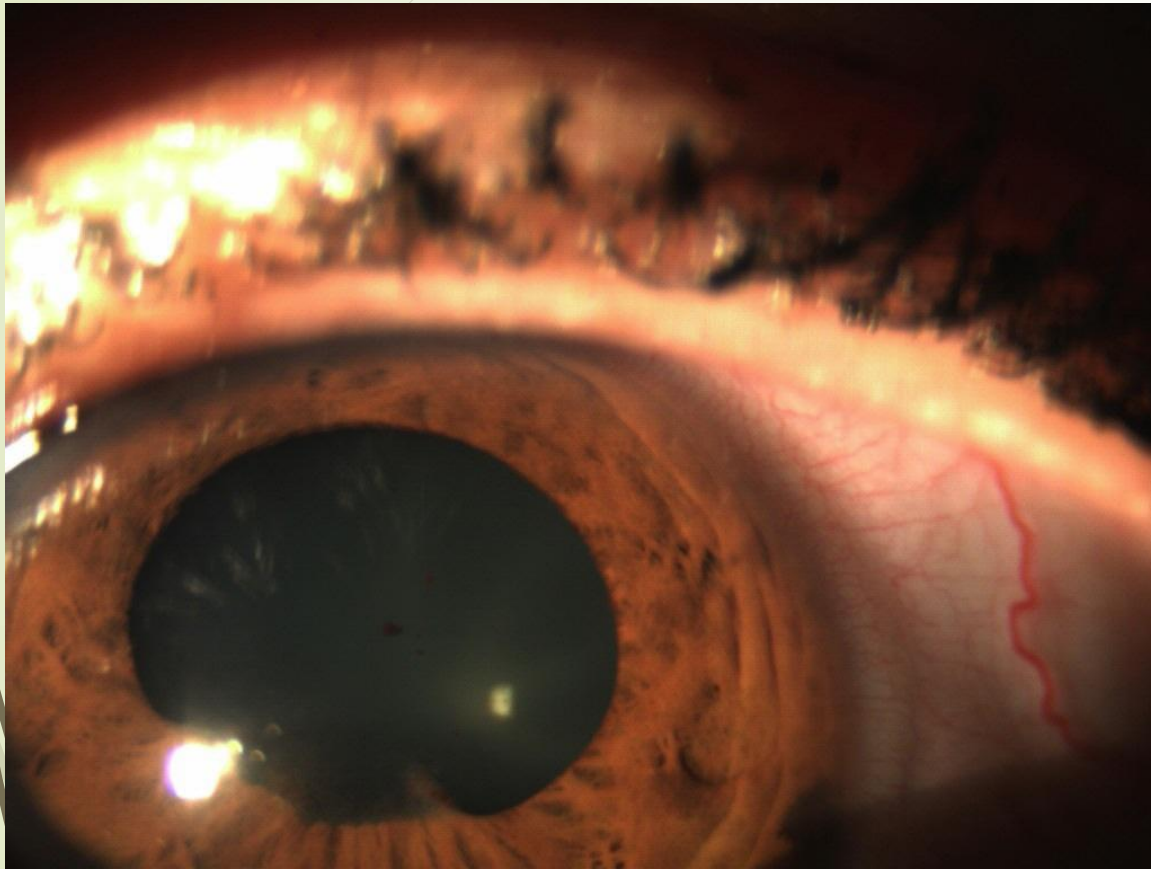
Treatment:

- oral methotrexate → in 6 weeks was switched to 12.5mg SQ (GI complaints)
- Folic acid, calcium
- naproxen BID that over next 4 weeks ↓ once or twice a week.
- Loratidine 5mg HS, do not replace the cat

Disease course:

- 13 months later he still has morning stiffness and has received 3 times intra-articular glucocorticoids in his right knee.
- Complaints once or twice a month of right hip pain. Normal MRI
- With reluctant parents, Etanercept is started at 25mg/ week (0.48 mg/kg/week)
- After week 4 the dose is increase to 50mg or 0.80 mg/kg / week
- In 2 to 3 weeks no swelling, no pain and BG returned to his normal activities .
- After 18 months without symptoms we started to decrease etanercept injection interval and then his dose was decreased to 25mg every 15 days, weaning period of 10 months.

Complications....



He had allergic rhinitis with poor compliance for allergic medication, IgE 279 IU/mL

28 months after JIA diagnosis presented with sinusitis with high fever so immunomodulatory meds were stopped.

He was supposed to reinstate his methotrexate and Etanercept but failed to do so.

Three months later started with red eye symptoms and used ophthalmic drops prescribed over the phone by general practitioner for allergic conjunctivitis.

After four days of increasing pain, an ophthalmologic evaluation revealed severe uveitis with synechia in right eye.

ANA negative with a SED rate of 20 mm/hr



Treatment:

- ▶ mydriatic cycloplegics topical and short course oral glucocorticoids,
- ▶ Restart etanercept at 50mg SQ and methotrexate

Wean off oral steroids over 3 weeks, and off eye drops in 8 weeks

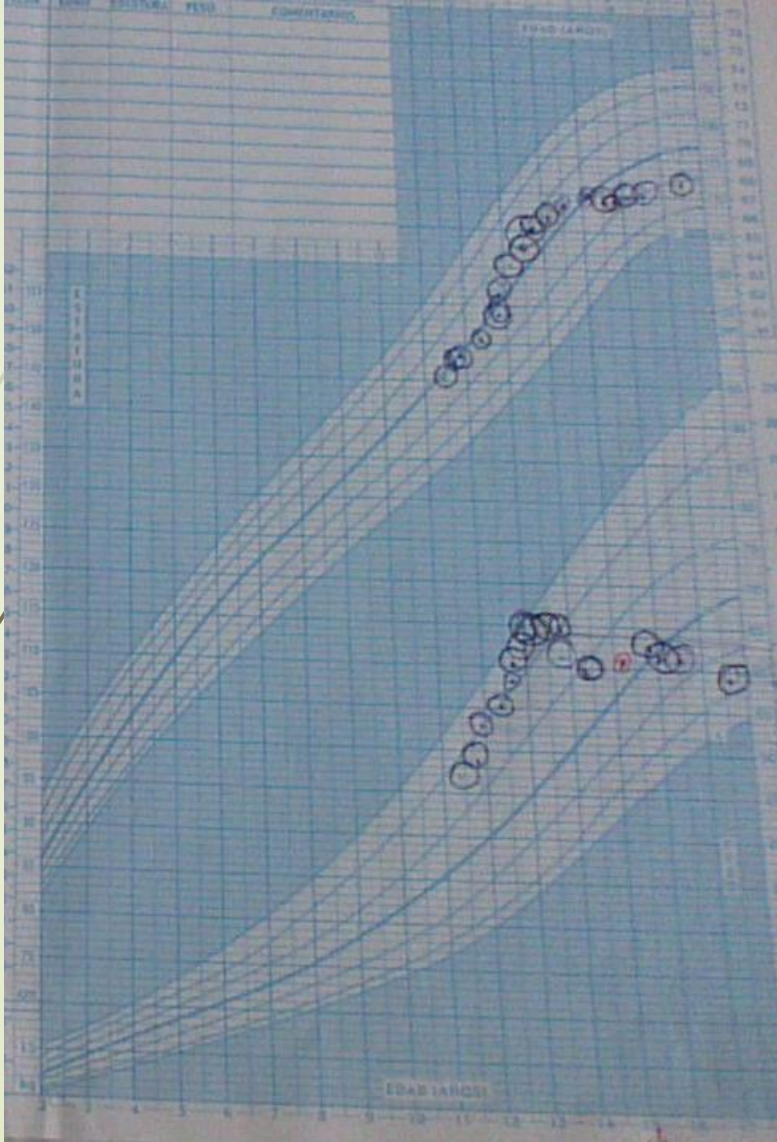
His TNF level slowly decreased to low levels over 6 months, although still higher than normal at 18-28 pg/mL

Resolution of synechia with some decrease of visual acuity

No synovitis, although a few episodes of hip pain, ultrasound studies normal, MRI of hips normal.

Has been symptom free for 18 months.

Summary of sequence of events



- 11, 6 years diagnosed and started on MTX
- 1 year with flares in knee, 3 courses of IA glucocorticoids
- 13 months after diagnosis started etanercept 25mg, increased dose in 4 weeks
- Good control after 1 month
- Symptom free for 18 months → weaning of etanercept up to 25mg every 15 days
- 26 months after diagnosis and 3 months after stopping etanercept and methotrexate develops **for the first time unilateral acute uveítis** without sinovitis or arthralgia or any other symptom.
- Sinechiae resolved after 1 month of treatment, but pdecreased visión acutiy and remained with high TNF for 6 months after stopping glucocorticoesteroids



Some themes to discuss

When and how to decrease biologic medication after control of symptoms is apparent

If uveitis is present, how should treatment and follow up be done? Acute vs Chronic change your approach?

How common is an activation of JIA or JAS presented only with uveitis?

Gracias



Thank you!

Muito Obrigada





RESEARCH ARTICLE

Open Access

Characteristics of a cohort of children with Juvenile Idiopathic Arthritis and JIA-associated Uveitis

Sheila T. Angeles-Han^{1,3,2*}, Courtney McCracken¹, Steven Yeh^{1,3}, Kirsten Jenkins², Daneka Stryker¹, Kelly Rouster-Stevens^{1,2}, Larry B. Vogler^{1,2}, Scott R. Lambert^{1,3}, Carolyn Drews-Botsch⁴ and Sampath Prahalad^{1,2,5}

- 10-25% of the 300,000 children in USA with JIA
- Develop during first 4 years of the arthritis diagnosis
- JIA-U is anterior, non-granulomatous chronic inflammatory, asymptomatic at onset
- Vision loss and ocular complications 3-66%